

Building Up a Totally New Tip in Patients with Severe Bulbous Noses

Wael M. SAADELDEEN, M.D.

The Department of Plastic Surgery, Faculty of Medicine and University Hospitals, Assiut, Egypt

ABSTRACT

Background: “Bulbous nose” is a term patients often use to describe a “ball” on the end of their nose. This ball can be caused by the abnormal anatomy of alar cartilage or by the overlying soft-tissue coverage [1].

Tip work is addressed by many surgeons to be the most sensitive aspect of rhinoplasty. This is because the nasal tip is the most complex area of the nose and its proper management requires three-dimensional consideration and thorough understanding. Thus, surgery for the nasal tip is the most challenging part of rhinoplasty, requiring ingenuity and flexibility on the part of the surgeon.

In severe bulbous noses, the problem is complex as it may not only include a large nasal tip, but also wide bony base and large flat dorsum. This large nasal tip can be caused by the abnormal anatomy at the nasal tip area which may include the skin, subcutaneous tissue, nasal superficial musculoaponeurotic system, ligaments, lower lateral cartilages (alar cartilages), and alar rims.

Goal: The universal goal of nasal tip surgery is to create a stable, symmetric, and aesthetically projected and rotated nasal tip that is triangular at base view and harmonious with the rest of the nose. In cases with severe bulbous shape, the nasal tip surgery will not conform to simplified rules. It will not be the rhinoplasty of a single technique as a sophisticated approach and an ability to use multiple techniques are keys for satisfactory results. Definition of the normal nasal beauty elements in noses with thick skin envelope yields on perfect strong underlying mixed skeletal support. Completing the nasal job in noses with thick skin is very critical to achieve a harmonious good-functioning nose.

Results: The author addressed a surgical technique for building up a totally new tip in patients with big skinny noses. The algorithm does not only refine the nasal tip, but also balance the whole nose in a way maintaining the functional as well as the aesthetic aspects of each individual bulbous nose. The algorithm focuses on definition of the aesthetic nasal tip elements in noses with thick skin envelope through building a perfect strong underlying skeletal support. The algorithm considers completing the nasal job in such noses very critical to achieve a harmonious good-functioning nose.

INTRODUCTION

The tip of the nose is the second most common area of concern for those considering rhinoplasty. It may be the only area of concern for some, and it may be addressed independently, without other procedures commonly associated with rhinoplasty surgery [1].

Tip work is addressed by many surgeons to be the most sensitive aspect of rhinoplasty. This is because the nasal tip is the most complex area of the nose and its proper management requires three-dimensional consideration and thorough understanding [2]. Thus, surgery for the nasal tip is the most challenging part of rhinoplasty, requiring ingenuity and flexibility on the part of the surgeon. Every surgeon should master several techniques of approach to and connection of anatomic variations of the nasal tip [3].

The “bulbous” nose is the term used by most rhinoplasty surgeons to describe a large nasal tip [4]. Also, it is a term patients often use to describe a “ball” on the end of their nose. Others use the term “bulbous nose” to describe not only large nasal tip, but also wide bony base and large flat dorsum [5]. This large nasal tip or that ball can be caused by the abnormal anatomy at the nasal tip area which may include the skin, subcutaneous tissue, nasal superficial musculoaponeurotic system, ligaments, lower lateral cartilages (alar cartilages), and alar rims [6].

The universal goal of nasal tip surgery is to create a stable, symmetric, and aesthetically projected and rotated nasal tip that is triangular at base view and harmonious with the rest of the nose [7]. In cases with severe bulbous shape, the nasal tip surgery will not conform to simplified rules. It will not be the rhinoplasty of a single technique

as a sophisticated approach and an ability to use multiple techniques are keys for satisfactory results [8]. Selection of appropriate techniques relies on a detailed preoperative assessment [9].

Care must be taken while operating such bulbous thick skin noses, as changing only the tip can change the whole balance of the nose [10]. So, the Rhinoplasty surgeon should never to offer a “short cut” or easy way to do a rhinoplasty in such complex noses, as it is inherently a complicated procedure that varies from individual to individual depending upon their nasal anatomy [11]. Definition of the normal nasal beauty elements in noses with thick skin envelope yields on perfect strong underlying mixed skeletal support [12]. Completing the nasal job in noses with thick skin is very critical to achieve a harmonious good-functioning nose [13].

Pathology of bulbous nose:

An understanding of the complexities of bulbous tip dynamics and a careful consideration of the patient’s nose overall anatomy and specific surgical goals will lead to the appropriate choice of tip-modifying techniques [14]. The effective surgeon will carry a fluid arsenal of tools into each tip rhinoplasty to use as each case requires [15].

Multiple anatomic causes for bulbous nasal tip exist. A weak cartilaginous structure and thickened nasal tip skin create a bulbous nasal tip with poor definition in most patients [16]. This is common in patients of African or Asian descent and can be very difficult to correct [17]. At times, a combination of thick skin and strong cartilage may contribute to bulbous nasal tip. Nasal skin varies as to volume and ability to contract; therefore, the shape, direction, or divergence of the individual crura cannot undergo unlimited modifications. Conversely, thin, relatively weak medial crural cartilages might not support tip grafts, and rather than increase projection, simply “melt” into the face as the medial crura buckle [18].

A bulbous nasal tip appearance may also result when lower lateral cartilages have strong bi-domal configurations. Excessive divergence of length of the middle crura can also contribute to a bulbous or boxy tip appearance [19].

Preoperative assessment:

Planning is the key to successful tip rhinoplasty. The surgeon should undertake a careful and methodical preoperative anatomic analysis. Each nose should be carefully evaluated. The surgeon should examine the bulbous tip, both visually and manu-

ally, to gain a detailed knowledge of the skin-soft tissue envelope and the underlying lower lateral cartilages. An intranasal examination is also a requisite part of any complete preoperative assessment [20].

Examination of other elements of the nose is of utmost importance since rhinoplasty is a complete-to-do job to obtain an aesthetically pleasant balanced nose and a good functioning one as well. Analyzing the relationship of the tip to the vault preoperatively is very critical, because it can create optical illusions [21]. The relationship of the tip to the rest of the nose can make a tip appear wider than it is physically, and therefore, a bulbous nose is relative. For example, a low, flat dorsum makes the tip appear larger. Similarly, excessive narrowing of the nasal base by alar wedges makes the tip appear wider again [22].

Very often in the bulbous wide nose, the nasal bridge bones are also wide. When doing the lateral osteotomies, one must be careful to not disrupt the structural support of the nose so that one’s breathing may be worsened. Because of this concern, improvement of a wide bony bridge may need to be done by building it up on top rather than narrowing at its base. This creates the illusion of a more narrow bridge. Such dorsal augmentation is usually done with cartilage grafts [23].

A list of problems should be outlined in order of priority following a thorough examination. The steps of surgery are carefully planned. The surgical plan may be modified during the procedure, but an organized approach is critical [24]. In severe cases of bulbous tip deformity, the surgeon has to do the greatest deformity first, whether it is tip or the dorsum; regardless, a “souffle” effect occurs. Thus, if the tip is done first, its skin cover will have more edema than if done last [25].

Complete nasal job in a bulbous wide nose with rhinoplasty will always improve how wide it appears. The outcome is a question of how much the nose (and specifically the tip) looks narrowed and is it enough to make the patient happy [26]. As many wide noses have thick skin, patients need to know that they will have more swelling which will last longer. This requires that patients have realistic expectations and good patience (two to four months) before the full shape of the nose from the rhinoplasty can start to be seen [27].

Careful photographic documentation is obtained preoperatively. A consistent format is used with identical lighting, background, and environment.

Use of digital photography systems facilitates consistent photodocumentation [28].

Each anatomic configuration has different solutions. "Cookie cutter" rhinoplasties do not exist. Instead, the experienced surgeon chooses from a variety of techniques, depending on the patient's individual anatomic characteristics [29].

There are several surgical possibilities for a given problem. Making the diagnosis of the underlying abnormal anatomy is the most important step; then the most appropriate operation can be selected. Struts, sutures, resection, dome division, and/or dorsal augmentation are all viable options for the management of the bulbous nose [30].

PATIENTS AND METHODS

Surgical technique:

The author used an surgical technique for building-up a totally new tip in the patients with bulbous tip deformity. This technique applied to selected 42 patients with severe bulbous tip and thick skin noses from the period of March 2008 till August 2013. This technique is constructed to guide the Rhinoplasty Surgeon making a new cartilaginous skeleton that gives impressions over the thinned-out thick skin envelope in such thick-skinned noses that need a strong reinforced structural support much like setting up a tent with a heavy thick envelope.

The length, strength, shape, and direction of the lower lateral cartilages were assessed to determine the combination of techniques that would be necessary to achieve the desired amount of tip projection and refinement. A stronger framework is needed to combat the healing contractile forces and the thick skin characteristics.

The author always starts with the greatest deformity first regardless if it was the tip or not and regardless the swelling may appear. The author uses the open approach in building-up the new tip in the patients with bulbous tip that required more detailed work than tip refinement. A transcolumellar v-shaped incision was made and connected with bilateral intracartilaginous incisions.

The author's surgical technique:

The nasal soft tissues were carefully separated from the lower lateral and upper lateral cartilages, dividing the suspensory ligament of the tip. The lower lateral cartilages were widely released from the upper lateral cartilages, from the septum at the

anterior septal angle, and from each other. Now, cancel the old tip defining points by cutting 3-4mm off the domes and cephalic excess of the lower lateral cartilage if hypertrophied; obliterate the inter-domal space, narrow the domal angles, and reduce the supra-tip fullness by excising a fibro-fatty tissue if present Figs. (1,2).

The author determined the source of the grafts he used to create the new skeleton for the new nasal tip. In most cases, the author used the septum as a source of choice. The auricle was rarely selected as it is a poor source for needed cartilage grafts. The costal cartilage often used as a rich donor site. The porous polyethylene sheaths of BOREX® used when the patient preferred synthetic source of support grafts.

The surgeon shaped out custom-made grafts he needed for every individual tip definition and support. He carved the raw sheet to a tip graft; long, medium, or small, cab Graft, columellar Strut, lateral crural struts, spreader grafts, dorsal graft, and caudal septal graft.

First, after lowering the tripod: 3-4mm of the domes excised, the surgeon inserted a columellar strut to add strong support and maintain good tip projection. The surgeon also applied 2 lateral crural struts. Suture control included: Trans-medial crural suturing the columellar strut. Trans-new domal, Inter-new domal, and Inter-crural sutures added for more stronger support. Now, a strong tri pillar structure formed and ready for the new tip elements to settle on Figs. (3,4).

The surgeon fulfilled the 6 tip characters: Volume, Width, Definition, Projection, Rotation, and Position. He fulfilled the tip volume by a proper tip graft, the width by size of the tip graft, and definition by proper size, shape, and resilience of the tip graft. Projection was fulfilled after good columellar strut application. Rotation, and position fulfilled using caudal septal graft together in harmony with proper suturing the new tip elements. Proper position then spontaneously fulfilled as a final result for fulfillment the previous 5 elements Fig. (5).

Thick skin refinement is achieved by either conservative shaving of the dermal layer from inside using the surgical blade number 22 or deep skin dermabrasion from the outside. Dermabrasion if done, addressed at the end of the operation and after complete suturing the open rhinoplasty incision.

The surgeon handled building-up the new tip here as a part of a complete nasal job. Careful

considerations should be taken to determine what every individual nose needed in addition to a new tip. Whenever the tip was of greatest concern, the author did the rest of Rhinoplasty steps after Building the new tip. In most severe bulbous noses, bilateral lateral osteotomies with dorsal augmentation were done. Some cases needed caudal septal graft, others were in need of basal alar resection. Spreader grafts applied routinely whenever the surgeon closed an open roof following mixed hump resection and rasping.

Postoperative details:

The postoperative swelling in patients with thick skin and especially with an open approach will last from months to years. Thus, oedema of the nasal tip will camouflage the underlying structured new tip. The surgeon informed all the patients that the final results may not be visible for 1-2 years. The surgeon injected dilute steroid subdermally at the tip region in patients with excessive swelling to accelerate resolution.

RESULTS

After a follow-up period of 12-18 months, all the patients showed increase of nasal tip definition. In addition, the desired triangular basal view has been obtained with a good tip support. The severely bulbous nasal tip became sharp once the edema disappeared, resulting in the desired nasal tip projection. Also, the nasolabial angle was markedly increased, and patients were therefore satisfied with the shape of their nose from both front and basal views. No instances of complications was found with the use of porous polyethylene synthetic grafts, such as infection, hematoma, necrosis of the skin, or perforation displacement. Moreover, open rhinoplasty scars from the incisions were invisible.

Complications:

Persistent supra-tip edema in 5 cases needed more deeper corticosteroids injections. Dorsal irregularities in 3 cases treated by diced cartilage emulsion injection.

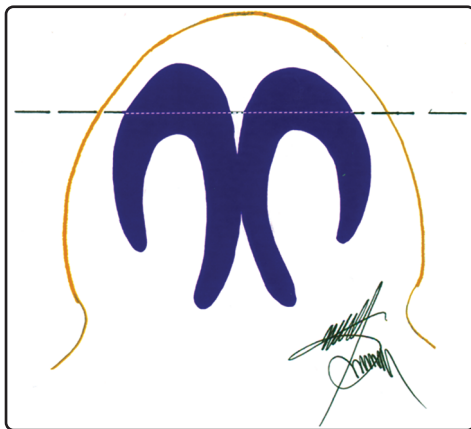


Fig. (1)




Fig. (2)




Fig. (3)

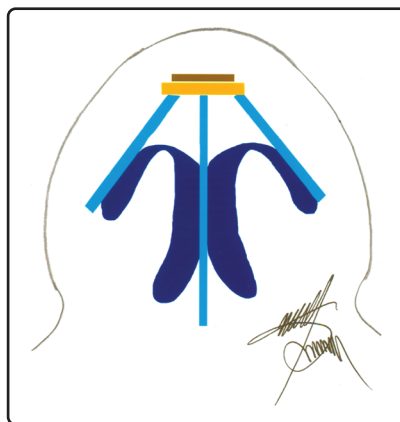


Fig. (4)

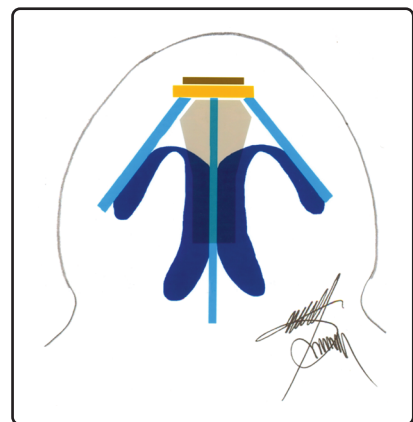


Fig. (5)

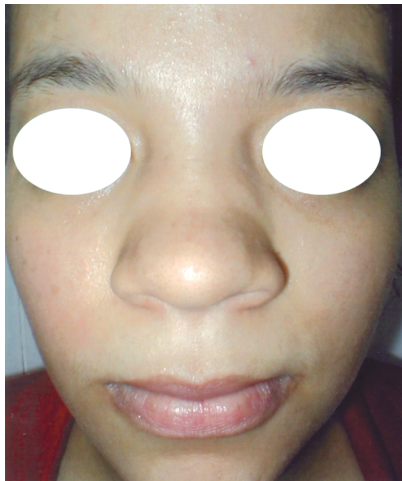

Fig. (6): Case (1): Preoperative anterior view.

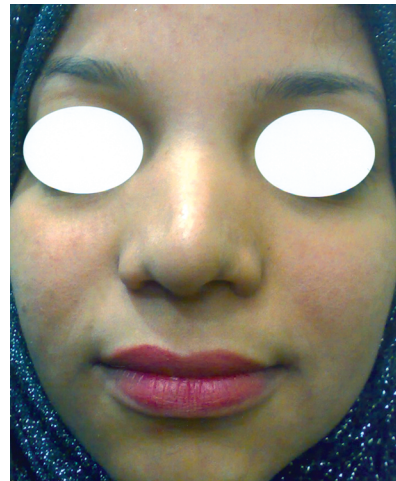

Fig. (7): Case (1): Post operative anterior view: Bilateral lateral basal and bilateral paramedian osteotomies done for bony pyramid erection in addition to double layered septal cartilage on-lay graft for the flat nasal dorsum. Two spreader grafts applied as well.

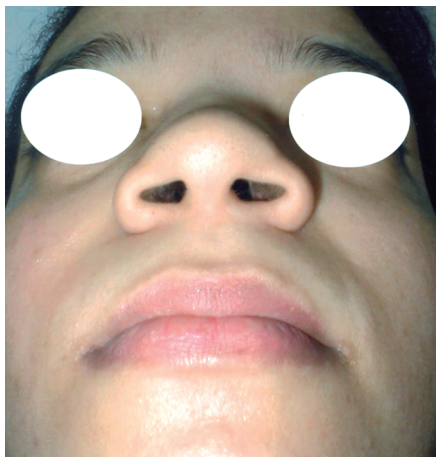

Fig. (8): Case (1): Preoperative basal view.

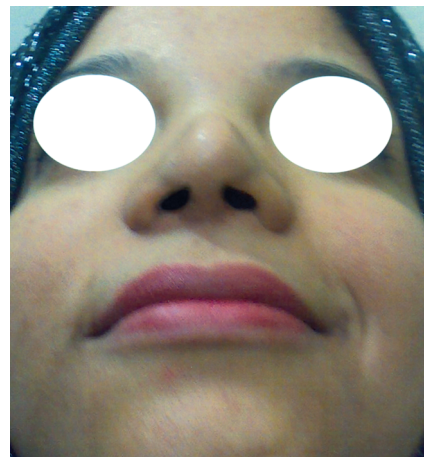

Fig. (9): Case (1): Basal view of Fig. (7): The desired triangular appearance of the nasal base achieved.

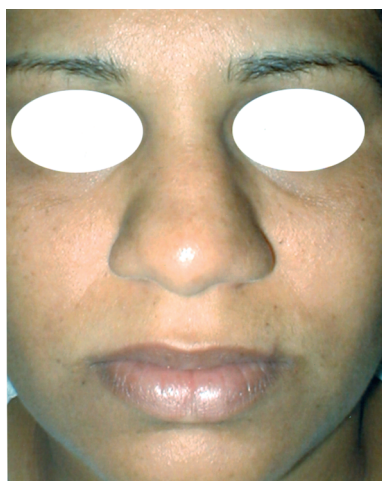

Fig. (10): Case (2): Preoperative anterior view.

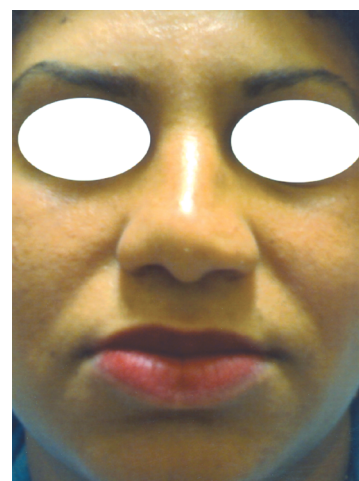

Fig. (11): Case (2): Post operative anterior view: Nasal dorsum was augmented with double-layered 1mm thickness 3-2mm wide Medpore sheet implant after bilateral basal and bilateral paramedian osteotomies. Two 1mm thickness Medpore spreader grafts applied.

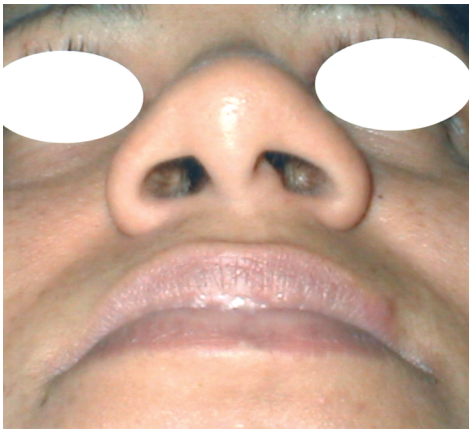

Fig. (12): Case (2): Preoperative basal view.

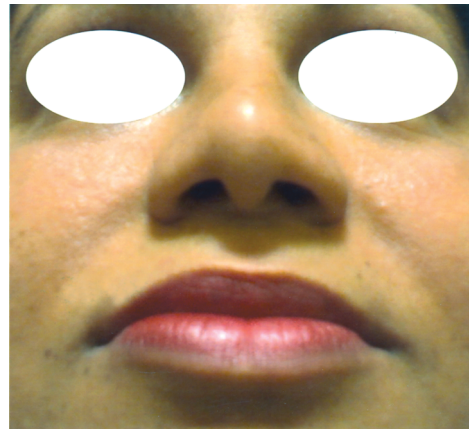

Fig. (13): Case (2): Postoperative basal view: The triangular shape obtained.

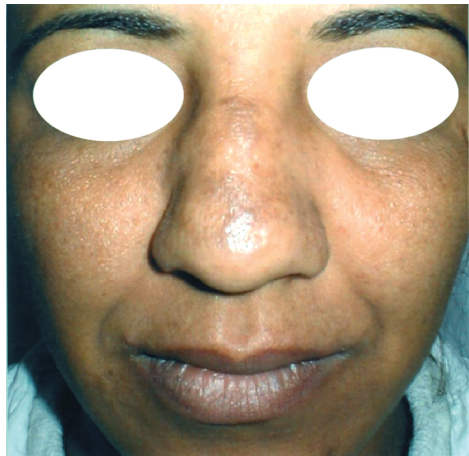

Fig. (14): Case (3): Preoperative anterior view.

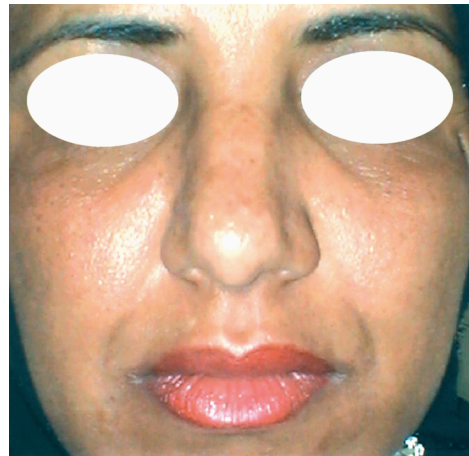


Fig. (15): Case (3): Post operative anterior view: The author used his algorithm to build a new tip, Triangular excision of the caudal septum for shortening of the long nose, tip rotation sutures, Bony pyramid work done the same as the previous 2 cases with wide base and flat vault. Spreader grafts routinely applied. The grafts source here was the rib cartilage.



Fig. (16): Case (3): Preoperative basal view.

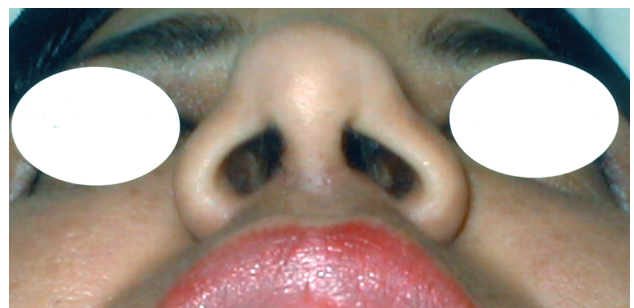


Fig. (17): Case (3): Postoperative basal view: The desired triangular basal view always obtained as a result.

DISCUSSION

While Rhinoplasty remains the most challenging cosmetic surgery procedure, Tip Rhinoplasty is considered the (Still Water That Runs Deep). Successful rhinoplasty operation may change the whole life of a person especially those suffering from very big bulbous and thick noses. Many Rhinoplasty

surgeons reject such cases in a smooth way informing the patient that she/he will get a very minimal or no percentage of improvement doing the surgery. While the incremental non-destructive techniques of columellar struts and tip sutures have been proved to achieve a desired refinement in most rhinoplasty patients, they are still not sufficient to make tip definition in bulbous noses with thick skin.

Conclusion:

The author's surgical technique approaching such a problem relies on the concept of building up a new stronger tip skeleton supported with strong pillars that shares in a new natural harmonically pleasant delicate appearance of a nose doing a complete nose job. The stronger new nasal tip skeleton will remain visible through the thinned-out envelope, the skin, giving the desired impressions, beauty points, lines, curves, and the balance between lights and shades at this central face area.

REFERENCES

- 1- Peter McKinney: Management of the Bulbous Nose. *Plast. Reconstr. Surg.*, 106 (4): 906-917, 2000.
- 2- Klinger M., Caviglioli F., Forcellini D., Bandi V., Maione L., Vinci V., pagliari A.V., Klinger F. and Mazzola R.F.: Primary Nasal Tip Surgery: A Conservative Approach. *Aesthetic Plast. Surg.*, 11 (15), 2001.
- 3- Lee K.C., Kwon Y.S., Park J.M., et al.: Nasal tip plasty using various techniques in rhinoplasty. *Aesthetic Plast. Surg.*, 28 (6): 445-55, 2004.
- 4- Rod J., Rohrich M.D. and Mark A. Deuber M.D.: Nasal Tip Refinement in Primary Rhinoplasty: The Cephalic Trim Cap Graft. *Aesthetic Surgery Journal*, Volume 22, Number 1: 39-45, 2002.
- 5- Romo T. III, Litner J.A. and Sclafani A.P.: Management of the severe bulbous nasal tip using porous polyethylene alloimplants. *Facial Plast. Surg.*, 19 (4): 341, 2003.
- 6- Patrocínio L.G. and Patrocínio J.A.: Open rhinoplasty for African-American noses, *Br. J. Oral Maxillofac. Surg.*, 01.011, 2007.
- 7- Constantian M.B.: The two essential elements for planning tip surgery in primary and secondary rhinoplasty: Observations based on review of 100 consecutive patients. *Plast. Reconstr. Surg.*, 114 (6): 1571-81, 2004.
- 8- Adamson P.A.: Nasal tip surgery in open rhinoplasty. *Facial Plast. Surg. Clin. North Am.*, 1: 39-52, 1993.
- 9- Sheen J.H.: Tip graft: A 20-year retrospective. *Plast. Reconstr. Surg.*, 91 (1): 48-63, 1993.
- 10- Tebbetts J.B.: Shaping and positioning the nasal tip without structural disruption: A new, systematic approach. *Plast. Reconstr. Surg.*, 94 (1): 61-77, 1994.
- 11- Simons R.L.: Management of the lower third of the nose: Vertical dome division. In: *Rhinoplasty: A Practical Guide to Functional and Aesthetic Surgery of the Nose*. Kugler Publications, 314-9, 1998.
- 12- Behzad Salari and Javad S. Totonchi: Evaluation of the Goldman tip procedure and suture technique in tip rhinoplasty. *Journal of Plastic, Reconstructive & Aesthetic Surgery*, 64 (4): 467-471, 2011.
- 13- Fernando Pedroza, et al.: The Tripod Graft: Nasal Tip Cartilage Reconstruction During Revision Rhinoplasty. *JAMA Facial Plast. Surg.*, 2013, 2348, 2014.
- 14- Horton C.E. and Matthews M.S.: Nasal reconstruction with autologous rib cartilage: A 43-year follow-up. *Plast. Reconstr. Surg.*, 89 (1): 131-5, 1992.
- 15- Dyer W.K. 2nd and Yune M.E.: Structural grafting in rhinoplasty. *Facial Plast. Surg.*, 13 (4): 269-77, 1997.
- 16- Gruber R.P. and Friedman G.D.: Suture algorithm for the broad or bulbous nasal tip. *Plast. Reconstr. Surg.*, 110 (7): 1752-64, 2002.
- 17- Kuran I., Tümerdem B., Tosun U., et al.: Evaluation of the effects of tip-binding sutures and cartilaginous grafts on tip projection and rotation. *Plast. Reconstr. Surg.*, 116 (1): 282-8, 2005.
- 18- Kridel R.W. and Konior R.J.: Controlled nasal tip rotation via the lateral crural overlay technique. *Arch. Otolaryngol. Head Neck Surg.*, 117 (4): 411-5, 1991.
- 19- Gunter J.P. and Friedman R.M.: Lateral crural strut graft: Technique and clinical applications in rhinoplasty. *Plast. Reconstr. Surg.*, 99 (4): 943-52, 1997.
- 20- Romo T. 3rd, Kwak E.S. and Sclafani A.P.: Revision rhinoplasty using porous high-density polyethylene implants to reestablish ethnic identity. *Aesthetic Plast. Surg.*, 30 (6): 679-84, 2006.
- 21- Swanepoel P.F. and Fysh R.: Laminated dorsi beam graft to eliminate postoperative twisting complications. *Arch. Facial Plast. Surg.*, 9 (4): 285-9, 2007.
- 22- Leach J.L. and Athre R.S.: Four suture tip rhinoplasty: A powerful tool for controlling tip dynamics. *Otolaryngol. Head Neck Surg.*, 135 (2): 227-31, 2006.
- 23- Horton C.E. and Matthews M.S.: Nasal reconstruction with autologous rib cartilage: A 43-year follow-up. *Plast. Reconstr. Surg.*, 89 (1): 131-5, 1992.
- 24- Daniel R.K.: Rhinoplasty and rib grafts: Evolving a flexible operative technique. *Plast. Reconstr. Surg.*, 94 (5): 597-609, 1994.
- 25- Dyer W.K. 2nd, Beaty M.M. and Prabhat A.: Architectural deficiencies of the nose: Treatment of the saddle nose and short nose deformities. *Otolaryngol. Clin. North Am.*, 32 (1): 89-112, 1999.
- 26- Gruber R.P., Pardun J. and Wall S.: Grafting the nasal dorsum with tandem ear cartilage. *Plast. Reconstr. Surg.*, 15; 112 (4): 1110-22, 2003.
- 27- Erdem T.: Long-term effectiveness of projection control suture in rhinoplasty. *Rhinology*, 48 (2): 189-94, 2010.
- 28- Fazil Apaydin: Lateral Crural Turn-in Flap in Functional Rhinoplasty. *Arch. Facial Plast. Surg.*, 7981-4, 2001.
- 29- Rohrich R.J. and Adams W.P. Jr.: The Boxy Nasal Tip; classification and management based on alar cartilagesuturing techniques. *Plast. Reconstr. Surg.*, 107 (7): 1849-63, 2001.
- 30- Gruber R.P., Kwon E., Berger A. and Belek K.A.: Supratip-plasty: A completely cartilaginous tip complex to maintain nasal tip width. *Aesthet. Surg.*, 1; 34 (1): 34-44, 2014.
- 31- Menick F.J.: Anatomic Reconstruction of the nasal tip cartilages in secondary and reconstructive rhinoplasty. *Plast. Reconstr. Surg.*, 104 (7): 2187-98, 1999.